

THORACIC SPINE TUBERCULOSIS PRESENTING WITH CHRONIC NAUSEA AND ABDOMINAL PAIN

SA Dhar, MR Mir, AR Badoo, MF Butt, TA Dar, MI Wani

Bone and Joint Surgery, Hospital Barzallah, Srinagar Kashmir, India

Abstract

Spinal tuberculosis usually presents with a particular and recognizable set of symptoms including, kyphosis, abscess formation and neurologic deficit. Tuberculosis of this region sometimes mimics some well known conditions like cholecystitis, pancreatitis and appendicitis. We report a case of thoracic spine tuberculosis presenting with nausea and abdominal pain. The case highlights the delay in diagnosis and the low suspicion of the tubercular origin of these symptoms.

Keywords: Tuberculosis, Abdominal pain, Nausea

Rezumat

Tuberculoză vertebrală manifestată prin greață și durere abdominală

Tuberculoza rahidiană se manifestă printr-un set de simptome și semne care includ cifoza, formarea de abcese reci și deficitul neurologic. Localizarea tuberculozei la acest nivel imită uneori boli obișnuite cum ar fi colecistita, pancreatita sau apendicita. Prezentăm aici un caz care s-a manifestat cu greață și dureri abdominale. Acesta ilustrează suspiciunea redusă de tuberculoză și întârzierea consecutivă a diagnosticului corect.

Cuvinte cheie: Tuberculoză, durere abdominală, greață

INTRODUCTION

Dorsal spine tuberculosis is the commonest type of tuberculosis involving the spine with a percentage occurrence of 42%. (1).

Clinically the tuberculosis of the spine presents with, clinical kyphosis (95%), palpable cold abscess (20%), radiological perivertebral abscesses (21%), sinuses (13%), extra spinal foci (12%), visceral foci (12%), neurological involvement (20%), lateral shift (5%), and skip lesions (7%). (2)

Unusually tuberculosis of the spine may present with clinical features of disc syndrome, appendicitis, cholecystitis, pancreatitis or renal disease.(2).

We present a case of chronic nausea and epigastric pain who was treated for both upper gastrointestinal and cardiac problems. Eventually the patients symptoms were traced to her thoracic spine tuberculosis. The patient was informed about the possibility of publication of her case history.

CASE HISTORY

A 35 year old female started having pain in the epigastric region with accompanying nausea in the late part of 2003.

There was no history of previous gastrointestinal disease or trauma.

After a month of treatment with proton pump inhibitors, the patient was referred to a tertiary hospital. This happened when the symptoms were especially painful.

A thorough work up was done which revealed a level of 8 gm/dl, TLC of 4000/cu mm, DLC showed polys 56 and lymphos of 38. An ultrasound showed slight pericardial effusion.

The proton pump inhibitors were continued. However there was no relief of symptoms. An additional month elapsed before an electrocardiogram was advised. The ECG revealed ST elevation in lead II and III. This was accompanied by bradycardia. A provisional diagnosis of inferior wall MI was formulated and a cardiac enzyme assay was ordered which proved to be negative.

The patient was discharged and asked to follow up on an outdoor basis. The patients symptoms persisted. An ESR was ordered which showed a result of 60 mm. A thorough examination was repeated and the only positive finding was tenderness in the D8 spine. Neurologic examination was carried out and no abnormality detected. An MRI was ordered, which showed a paradiscal lesion in the thoracic region. A polymerase chain reaction for tuberculosis turned out to be positive. The patient was put on anti tubercular therapy and there was

complete relief of symptoms. At one year of follow up the patient was symptomfree with an ESR of 5.

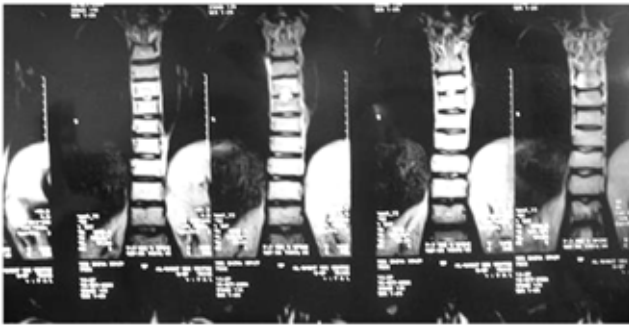


Figure 1

MRI showing involvement of the thoracic spine with the paradiscal variety of tuberculosis

DISCUSSION

Compressive myelopathy of thoracic cord may present shoulder, cardiothoracic, abdominal and pelvic symptoms. (3,4,5). This may spur an extensive work up for as long as one year before a patient is referred. (6).

Caries spine may give rise to similar situations with a clinical spectrum ranging from fibro fasciitis, cervicodorsal spondylosis or disc syndrome. (7).

Pain referred to the abdomen may need differentiation from appendicitis, cholecystitis, pancreatitis or renal disease. (7).

It is important that this atypical presentation be diagnosed early to prevent problematic sequelae. The atypical situation is mentioned in literature. However it continues to be a rare situation. (4,5,6).

Mechanism of referral of pain in such situations is unclear. Visceral and somatic afferent fibers have been attributed to different spinal locations including dorsal columns, spinothalamic and spinocortical tracts as well as dorsal and ventral horns. (8).

The anatomic location in an axial cross section of the cord in which visceral pain is processed is still controversial. (8).

It is possible that hyperexcitability at the site of the visceral afferent processing due to inflammation causes pain. (6).

It is also plausible that a biological or mechanical effect could interfere with the descending inhibitory systems that are known to modulate neurons that receive noxious input. (9).

The fact that our case underwent extensive work up, highlights the fact that the suspicion for atypical presentation of caries spine continues to be low.

REFERENCES

1. Paus B – Treatment for tuberculosis of the spine. *Acta Orthop Scand (Suppl)* 72, 1964.
2. Tuli SM – Tuberculosis of the skeletal system 2nd edition. 1997. page 180. Jaypee brothers.
3. Whitcomb DC, Martin SP, Schoen RE – Chronic abdominal pain caused by thoracic disc herniation. *Am J Gastroenterology* 1995; 96; 835-7.
4. Wilke A, Wolf U, Lageard P et al – Thoracic disc herniation. A diagnostic challenge. *Man Ther.* 2000; 5; 181-4.
5. Xiong Y, Lachman E, Marini S et al – Thoracic disc herniation presenting as abdominal and pelvic pain; a case report. *Arch Phys Med Rehab* 2001; 82; 1142-4.
6. Rachel S, Kang JD – Thoracic disc herniation presenting with chronic nausea and abdominal pain. *JBSJ (Am)* vol 86, feb 2004.
7. Tuli SM – Tuberculosis of the skeletal system 2nd edition . 1997 page 178-182. Jaypee brothers.
8. Al Chaer ED, Laward NB – Visceral nociceptive input into the ventral posterolateral nucleus of the thalamus; a new function for the dorsal column pathway. *J neurophysiology* 1996; 76; 2661-74.
9. Mayer EA, Gebhart EF – Basic and clinical aspects of visceral hyperalgesia. *Gastroenterology* 1994; 107; 271-293.