

PARANEOPLASTIC RAYNAUD'S PHENOMENON AND DIGITAL ISCHAEMIA AS A PRESENTING FEATURE OF UNDERLYING

D Ashok, Elaine Baguley

Rheumatology Department, Buckinghamshire Hospitals NHS Trust and Rheumatology Department, Hull Royal Infirmary, UK

Abstract

Late onset Raynaud's, rapidly worsening, poses a diagnostic challenge. Rarely may it be associated with underlying malignancy. Associated autoantibody positivity may cause diagnostic delay. We describe three cases who sought treatment for Raynaud's subsequently diagnosed with malignancy, treatment of which improved the Raynaud's. We discuss the possible mechanisms.

Keywords: Raynaud's, Digital ischaemia, Malignancy, Paraneoplastic

Rezumat

Sindrom Raynaud paraneoplazic

Sindromul Raynaud cu debut tardiv și evoluție rapid progresivă ridică probleme de diagnostic. Uneori acesta poate fi asociat unei neoplazii. Testele pozitive pentru unii autoanticorpi pot duce la întârzierea diagnosticului. Prezentarea se referă la trei cazuri de sindrom Raynaud care în cele din urmă au fost diagnosticate ca fiind paraneoplazice și la care tratamentul bolii de bază a dus la ameliorarea stării vasculare. Posibilele mecanisme sunt discutate.

Cuvinte cheie: Fenomen Raynaud, ischemie digitală, neoplasm, sindrom paraneoplazic

Raynaud's phenomenon (RP) first described by Maurice Raynaud 1862 is characterised by reversible vasospasm in response to cold or emotion. In young patients it is commonly hereditary but after the second decade its onset is often linked with underlying causes particularly scleroderma and systemic lupus erythematosus. Other conditions including emboli, hemostatic abnormalities, trauma and the use of vasoconstrictive drugs may produce symptoms mimicking RP (1).

Rapidly worsening RP poses a diagnostic and therapeutic challenge. Rarely may it be associated with underlying malignancy. We present three patients who presented with RP and other features of connective tissue disease where further investigations revealed undiagnosed malignancy and review possible mechanisms.

both hands were cyanotic (Figure 1, 2 and 3), and all the peripheral pulses were present. He had a few mouth ulcers, cervical and inguinal lymphadenopathy, mild splenomegaly and synovitis of the elbows. He was admitted to the hospital and commenced on Nifedipine.

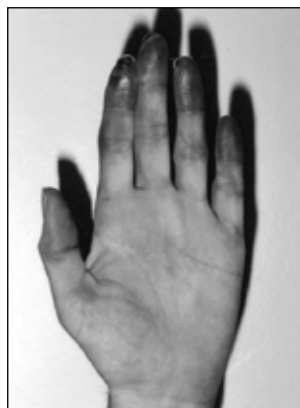

Figure 1

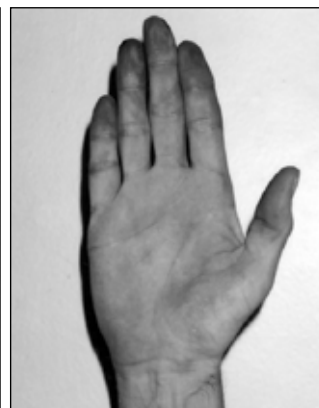


Figure 2



Figure 3

CASE REPORTS

Case 1. A previously well 44-year-old man presented with six week history of painful shoulders and elbows, and two week history of blue discoloration of the fingers. He had a history of smoking and recent loss of appetite. He was not taking any vasoconstrictive drugs. On examination fingers on

Table 1
Summarised Results of all Laboratory Tests

	Case 1	Case 2	Case 3
FBC	Normal	Normal	Normal
Plasma viscosity (Normal range 1.50-1.72)	1.74	2.06	
C-reactive protein (crp) (Normal range 0-8 mg/dl)	87	Normal	13
Biochemical profile	Normal	Normal	Normal
CPK (Normal range 55-200 IU/L)	56		293
Septic screen	Negative		
Serum complement levels	Normal		
Rheumatoid factor	Negative	Negative	Negative
Antinuclear antibodies	Negative	1/640, speckled	1/320, speckled
DNA		Negative	Negative
RNP		Positive	Negative
ANCA	Negative		
Cryoglobulins	Negative		
Cold agglutinins	Negative		
LDH (Normal range 100-250 IU/L)		647	
Hepatitis B and C viruses	Negative		

Results of the tests are summarised in table 1.

He developed digital ulceration (Figure 3) despite intravenous prostacycline, aspirin, clopidogrel and nifedipine. CT scan of chest and abdomen revealed bilateral axillary and inguinal lymphadenopathy with a marginally enlarged spleen. Lymph node biopsy showed B- cell chronic lymphocytic leukaemia (CLL), biopsy of the bone marrow did not reveal any infiltration by the CLL. He was commenced on 60 mg prednisolone. He required re admission for further prostacycline infusions and surgical debridement of the digital ulcers.

He was commenced on azathioprine 2 mg/kg body weight with gradual reduction of prednisolone and regularly reviewed in the rheumatology clinic. His finger ulcers healed and he experienced no further episode of digital ischaemia after 12 months of follow up. No further treatment was deemed necessary for his CLL.

Case 2. A 64-year-old woman was referred urgently from A+E to the Rheumatology department

with an eight week history of new onset, rapidly worsening RP. She had experienced intermittent skin rashes in the past for which she was under a dermatologist. She was non smoker, and had commenced nifedipine three days prior to her admission. Physical examination showed cyanosed fingers and firm mass in the left axilla.

Results of the blood tests are in table 1.

Ultrasonography and biopsy of the mass in the left axilla revealed metastatic carcinoma suggestive of breast cancer. She was commenced on chemotherapy and subsequently radiotherapy. Subsequently she has had no further episodes of digital cyanosis with her Raynauds requiring minimal therapy.

Case 3. A 58-year-old woman was referred to the Rheumatology clinic with an eight week history of joint pains associated with swelling affecting wrists, and hands, recent onset of RP and dry eyes and mouth. Her past medical history included hypothyroidism, bilateral carpal tunnel release and a recent review by the Maxillo- facial surgeon for bilateral parotid swelling.

Physical examination revealed mild bilateral parotid swelling, dusky hands with abnormal nail fold capillaries and synovitis affecting the proximal and distal interphalangeal joints. She was commenced on nifedipine and hydroxychloroquine and regularly reviewed in the clinic, with a presumptive diagnosis of an evolving connective tissue disease.

Results of the blood tests are shown in table 1.

Over the course of next six months she developed sore finger tips, discolouration over the knuckles and mild proximal muscle weakness with raised muscle enzyme CPK 310 (24-170). She was commenced on prednisolone 20 mg per day with improvement in the symptoms.

A year after her original presentation, she was admitted with right loin discomfort and haematuria. A renal ultrasound scan showed a solid mass in the right kidney consistent with renal cell carcinoma. Further imaging revealed multiple pulmonary metastasis. She underwent right radical nephrectomy and had a good postoperative recovery with improvement of all musculoskeletal symptoms being able to stop steroids completely. She was commenced on immunotherapy for the metastatic disease without subsequent relapse of any musculoskeletal symptoms.

DISCUSSION

The association between malignancy and musculoskeletal disease is complex and intriguing. A search of the Medline database by Poszepczynska-Guigne et al (1) identified 66 previously reported cases of paraneoplastic Raynaud's with two new cases in their report. The malignancies that have been associated with RP include carcinoma of the lung, stomach, colon, small intestine, pancreas, uterus, ovary, kidney and maxillary antrum, myeloma, melanoma, leukaemia and lymphoma (3,4).

Unlike primary RP which predominantly affects young women, paraneoplastic RP almost equally affects both sexes at an older mean age (5). The onset may be of short duration, with severe, asymmetric involvement of the digits. More than 80% of patients progress to ischemia, necrosis, pulp atrophy and gangrene. The evolution of paraneoplastic RP is similar to that of other paraneoplastic syndromes. Our first patient had short duration of symptoms, asymmetric involvement, and rapidly developed necrosis of the digits.

There are several mechanisms suggested whereby malignancy could lead to digital ischemia including

sympathetic hyperactivity, cryoglobulinemia, immune – complex – induced vasospasm, vasculitis, hypercoagulable state, antiphospholipid antibodies, and marantic endocarditis with embolic phenomena (6,7). Multiple mechanisms may be involved in a case.

Arteritis of diverse etiologies has been associated with digital artery vasospasm, as well as with digital artery obstruction producing finger ischemia and finger gangrene (8). The cause of the arteritis is unknown but may be related to tumour antigen – antibody complexes with subsequent complement activation in contact with the arterial wall. The induction of vasculitis by antibodies to tumour antigens has been suggested as a possible mechanism (9). Digital ischaemic symptoms have been reported to improve after removal of renal carcinoma and ovarian carcinoma, with recurrence indicating relapse (9,10). The improvement in digital symptoms following treatment of breast cancer with chemotherapy followed by radiotherapy as in our second patient and surgery for renal cancer as in our third patient may be in keeping with the suggestion that tumour antigen contributes to the pathogenesis.

The immune system plays a central role in cancer both in vigilance for atypia and in the symptomatology of cancers. A balance exists between immune response and tolerance or ignorance of tumour antigens. Dendritic cells are at the centre of this balance. Uncontrolled exponential expansion of lymphocytes and unchecked cytokine production and cytotoxic activity may lead to autoimmunity (11). An understanding of these control mechanisms of immune activation has helped to optimise the design of immunotherapy intervention and cancer vaccine development (11,12). Monoclonal antibodies to surface receptors, such as rituximab, have complex mechanisms of action leading to effective tumour regressions. Stimulation of antibody-dependent cell mediated cytotoxicity together with ability of immune complexes to allow antigen cross-presentation in dendritic cells, may contribute to their antitumor effects by a coordinated humoral and cellular response (13,14,15). Resultant tumour cell damage and cross-presentation of antigen by host APCs (antigen presenting cell) may allow the transfer of the immunologic stimulus to cellular immune responses (16) leading to trials in auto immune disease where improvement has also been observed. Cancer immunotherapy attempts to shift the balance of the immune system

toward rejection of cancer. The therapeutic window may be narrow between antitumor immune response and autoimmunity, but also between response and tolerance to tumour antigens.

CONCLUSION

In conclusion Raynaud's as a presenting feature of malignancy is rare, when it does occur it tend to

be severe and requires aggressive treatment. Improvement can be seen following treatment of underlying malignancy as in our two cases. An immunological mechanism has been suggested.

All three patients exhibited a rapid evolution of symptoms with markedly symptomatic RP. Even in the presence of positive auto antibodies we would suggest that malignancy is considered in patients with atypical presentations.

REFERENCES

1. **Poszepczynska E, Viguier M, Chosidow O, Orcel B, Emmerich J** – Paraneoplastic acral vascular syndrome; epidemiologic features, clinical manifestations and disease sequelae. *J Am Acad Derm* 2002; 47-52.
2. **Tolosa-vilella C, Ordi-Ros J, Vilardell-Tarres M, Selva, Callaghan A, and Jordana - Comajuncosa R** – Raynaud's phenomenon and positive antinuclear antibodies in a malignancy. *Ann of the Rheum Disease* 1990;49: 935-936.
3. **DeCross AJ, Sahasrabudhe DM** – Paraneoplastic Raynaud's phenomenon. *Am J Med* 1992; 5: 571-572.
4. **Kohli M, Bennett RM** – Raynaud's phenomenon as a presenting sign of ovarian adenocarcinoma. *J Rheumatol* 1995; 22: 1393-1394.
5. **Priollet P, Vayssairat M, Housset E** – How to classify Raynaud's phenomenon. Long term follow-up study of 73 cases. *Am J Med* 1987; 83:494-8.
6. **Alvin S, CW, Kam, HY** – Paraneoplastic Raynaud's phenomenon and idiopathic thrombocytopenic purpura in non-small-cell lung cancer. *Am J of clin onco*; vol26 (1) Feb 2003; 26-29.
7. **Taylor LM Jr, Hauty MG, Edwards JM, Porter JM** – Digital ischemia as a manifestation of malignancy. *Ann Surg*; July 1987; vol 206: 62-68.
8. **Taylor L.M Jr, Baur GM, Portter JM** – Finger gangrene caused by small artery occlusive disease. *Ann Surg* 1981; 193; 543-561.
9. **Andrasch RH, Bardana EJ, Porter JM, Pirofsky B** – Digital ischaemia and gangrene preceding renal neoplasm. *Arch Intern Med* 1976; 136:486-488.
10. **Maurice PDL** – Ovarian carcinoma and digital ischaemia. *Clin Exp Dermatol* 1996; 21:381-382.
11. **Ribas A, Butterfield LH, Glaspy JA, Economou JS** – Current development in cancer vaccines and cellular immunotherapy. *Journ of clin onco*; Vol 21, 2003; 2415-2432.
12. **Waldmann TA** – Immunotherapy; Past, Present and future; *Nature Med*; vol 9, March 2003.
13. **Gura, T** – Magic bullet hit the target. *Nature* 417, 584-586, 2002.
14. **Cynes RA, Towers TL, Presta LG et al** – Inhibitory fc receptor modulate in vivo cytotoxicity against tumor targets. *Nat Med* 6; 443-446, 2000.
15. **Kalergis AM, Ravetch JV** – Inducing tumor immunity through the selective engagement of activating Fc gamma receptors on dendritic cells. *J Exp Med* 195; 1653-1659, 2002.
16. **Schuurhuis DH, Ioan-Facsinay A, Nagelkerken B, et al** – Antigen-antibody immune complexes empower dendritic cells to efficiently prime specific CD8+CTL response in vivo. *J Immunol* 168; 2240-2246, 2002.