

## CEREBELLAR GLIOBLASTOMA IN THE ELDERLY – CASE REPORT

Boris Božić<sup>1</sup>, Krešimir Rotim<sup>1</sup>, Andrej Kogler<sup>1</sup>, Ranko Broz<sup>1</sup>, Hrvoje Krpina<sup>1</sup>, Hrvoje Čupiće<sup>2</sup> and Jasna Radić<sup>3</sup>

<sup>1</sup>University Department of Neurosurgery, <sup>2</sup>Ljudevit Jurak University Department of Pathology, <sup>3</sup>University Department of Oncology and Nuclear Medicine, Sestre milosrdnice University Hospital, Zagreb, Croatia

**SUMMARY** – Cerebellar glioblastoma in the elderly is rare. Only 33 cases have been reported in the literature. We report on a 65-year-old male patient with cerebellar glioblastoma. Computed tomography scan revealed a posterior fossa tumor of 34x33x52 mm in size, with hydrocephalus. The patient presented with posterior fossa symptoms, ataxia, nausea and vomiting. He deteriorated rapidly and ventricular drainage was performed. When the patient's condition improved, suboccipital median craniectomy was performed and the tumor was removed. Postoperative treatment included radiotherapy and temozolomide chemotherapy.

**Key words:** *Brain neoplasms – diagnosis; Brain neoplasms – surgery; Glioblastoma – diagnosis; Glioblastoma – surgery; Aged; Case Report*

### Introduction

Glial tumors are the most common brain tumors. They arise from neuroepithelial cells and account for 40% of all intracranial tumors and 78% of all malignant central nervous system (CNS) tumors. According to the World Health Organization (WHO), they are divided into three basic groups: astrocytic tumors, oligodendrocytic tumors, and ependymomas. Astrocytic tumors, known as astrocytomas, account for 75% of all glial tumors. Histologic analysis shows them to consist of astroglial cells. WHO classifies astrocytic tumors according to the surrounding tissue involvement. Pilocytic astrocytomas are well limited, diffuse astrocytomas infiltrating surrounding tissue. Anaplastic astrocytomas have higher cellular density than diffuse astrocytomas. Glioblastomas are the highest level of astrocytic tumors characterized by malignancy, polymorphism, tumor cell mitosis and neovascularization. Glioblastoma is the final step of astrocytic tumor development and accounts for 12% to 15% of all

intracranial tumors. Although it may occur in all age groups, it is usually seen in people over 50 years of age. The male to female ratio is 1.4:1.8. Some 8% of glioblastomas are found in children. Congenital glioblastoma is rare. It is usually located in white matter of cerebral hemispheres. The tumor is most commonly localized in temporal lobes (31%) and least frequently in occipital lobe. Brain stem glioblastoma is rare and usually seen in children. Spinal and cerebellar glioblastomas are also infrequently observed. The main characteristic is diffuse and infiltrative growth following white matter pathways, even through corpus callosum (butterfly tumors). Metastatic tumors are rare, and only a few cases of multiple glioblastomas have been reported (gliomatosis, WHO stage III and IV). These glioblastomas are often polyclonal.

### Case Report

On November 11, 2006, a 65-year-old man was admitted to Department of Medicine because of vomiting, nausea, vertigo and occipital headache. He had a history of elevated blood pressure and coronary disease. He was shortly checked by a neurologist, and computed tomography (CT) of the brain was performed to show a

Correspondence to: *Hrvoje Krpina, MD*, University Department of Neurosurgery, Sestre milosrdnice University Hospital, Vinogradska c. 29, HR-10000 Zagreb, Croatia  
E-mail: hkrpina@globalnet.hr

Received February 6, 2009, accepted April 16, 2009

posterior fossa lesion measuring 34x33x52 cm (Figs. 1 and 2), with fourth ventricle compression and dislocation. Supratentorial ventricles showed dilatation with third ventricle width measuring 21 mm. The patient deteriorated rapidly, was transferred to neurosurgery and underwent emergency surgery. Ventricular drainage was performed, measuring 60 cm water pressure in the right lateral ventricle. Upon improvement and stabilization, the patient underwent another surgical procedure. Suboccipital medial craniectomy was performed and the tumor was microsurgically removed (Fig. 3). On histopathology, the tumor was identified as glioblastoma (Figs. 4 and 5). Postoperative CT scan showed tumor removal and no sign of hydrocephalus, so ventricular drainage was also removed. Four weeks after the surgery, radiotherapy and temozolomide chemotherapy were introduced. Radiotherapy was administered to tumor cavity and surrounding tissue at a dosage of 60 Gy in 30 fractions over 6 weeks. A year after treatment, the patient resumed his job as a musician and composer.

## Discussion

Glioblastoma is the least differentiated malignant brain tumor. Histopathologic characteristics include cell polymorphism, atypical appearance, high mitosis ratio, microvascular proliferation, and frequent tumor necrosis. The tumor develops as a secondary tumor from diffuse (WHO grade II) or anaplastic (WHO grade III) astrocytoma. It can manifest as a primary tumor without any clinical or histopathologic evidence of previous tumor existence. In the last years, the concept of different genetic pathways of primary and secondary glioblastomas has been accepted. Genetically, primary and secondary glioblastomas are two different forms of the same disease. Cerebellum is a rare localization of glioblastoma. To date, 33 cases of cerebellar glioblastoma have been reported in the literature. Glioblastomas of this localization usually are primary tumors without clinical, radiologic or histopathologic evidence of a previous tumor.

The treatment of glioblastoma includes neurosurgical resection, histopathologic verification, and in extension radiotherapy and chemotherapy. According to the extent of neurosurgical resection, radical tumor removal has been associated with a higher survival rate than biopsy or smaller resection. The presence or higher extent of necrosis is linked with poorer life expectancy prognosis. Radiotherapy is administered upon the tu-

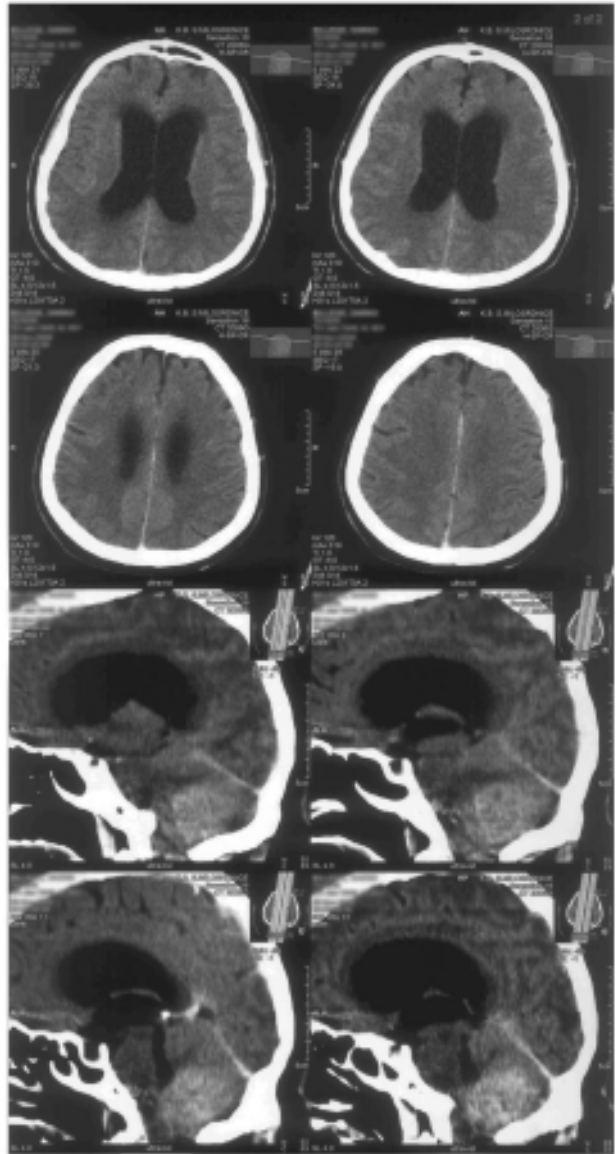


Fig. 1. Computed tomography scan of the brain: axial slice – contrast enhanced posterior fossa lesion.

mor and 3-cm margins of the surrounding brain tissue, at a dosage of 60 Gy in 30 fractions 5 times a week for 6 weeks. Median survival in patients operated on is 7 months, increasing to 15 months with radiotherapy and concomitant temozolomide chemotherapy. Chemotherapy of brain tumors is limited by the blood-brain barrier. Only small molecules such as nitrourea derivatives can cross the barrier. Sporadic responses to chemotherapy do not last long, due to the fast development of resistance to therapy as the result of gene transformation and tumor heterogeneity. Median survival increases to

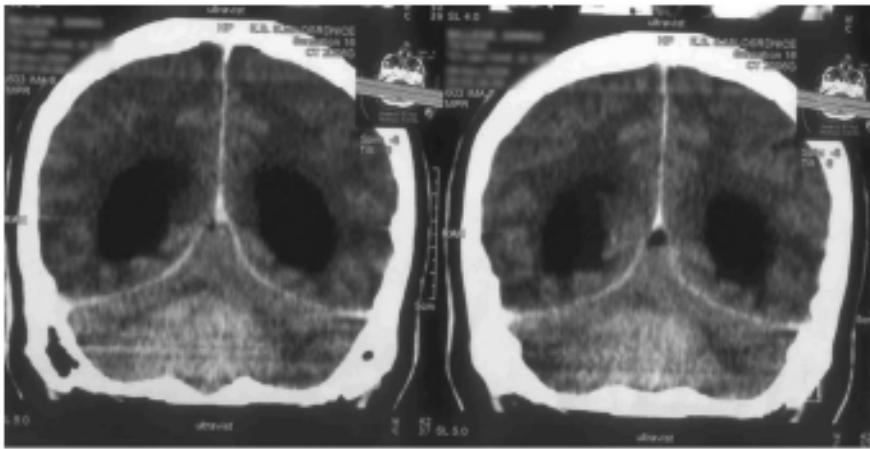


Fig. 2. Computed tomography scan of the brain: coronal slice reconstruction – contrast enhanced posterior fossa lesion.

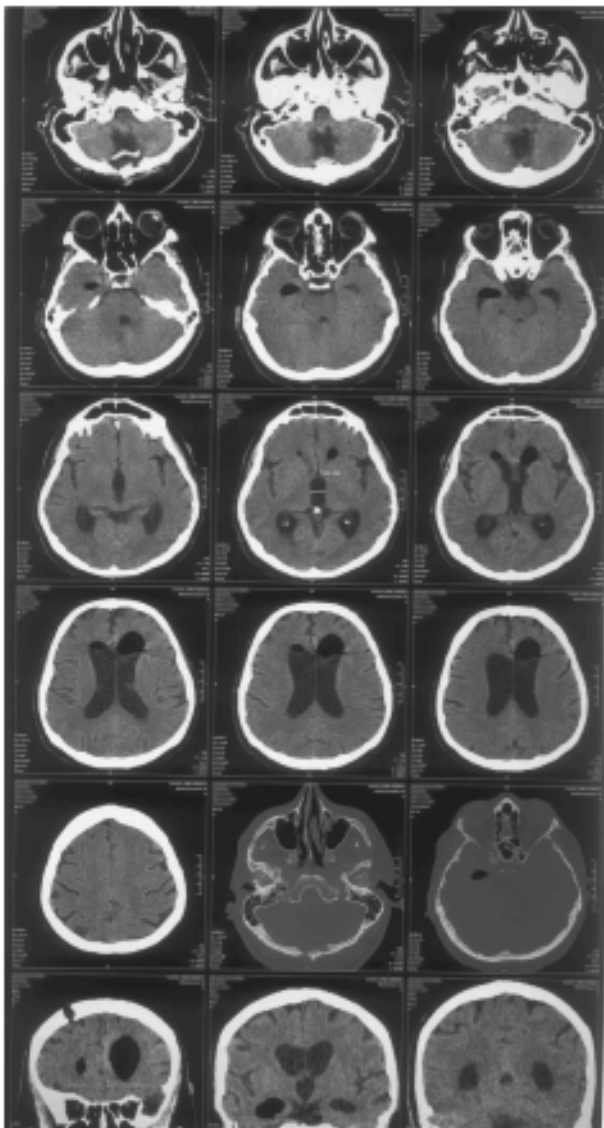


Fig. 3. Computed tomography scan of the brain: axial and coronal reconstruction slices – postoperative images.

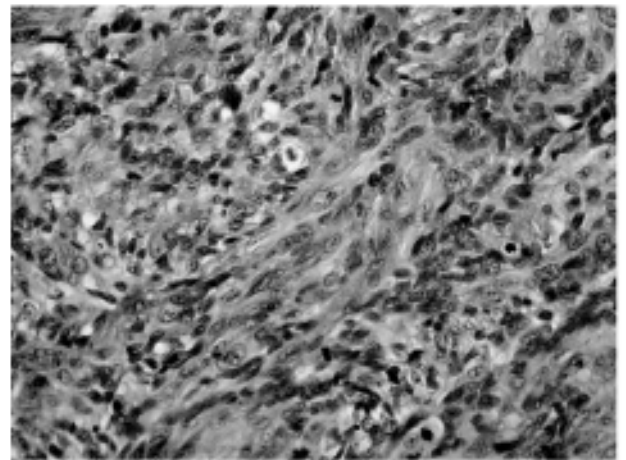


Fig. 4. Histopathologic findings (Mallory; magnification X400).

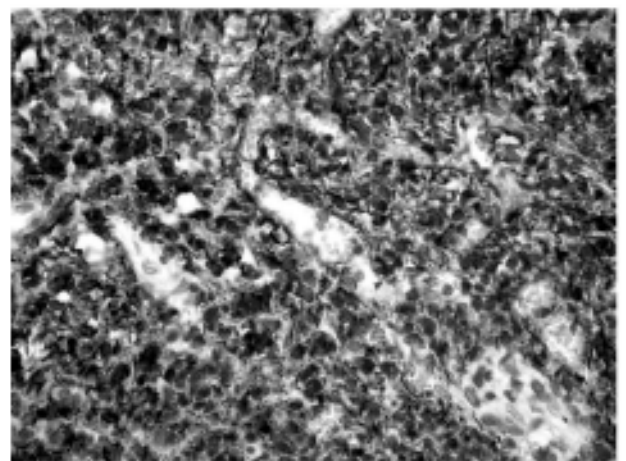


Fig. 5. Histopathologic findings (GFAP; magnification X400).

24 months with postoperative administration of temozolomide along with radiotherapy.

## References

1. CHAMBERLAIN MC, SILVER P, LEVIN PA. Poorly differentiated gliomas of the cerebellum. A study of 18 patients. *Cancer* 1990;65:337-40.
2. TONORI T, TSUNEYOSHI E, MASAKI S, AKIRA T. Glioblastoma multiforme of the cerebellum in an elderly man. *J Chin Med Assoc* 2004;67:301-4.
3. DOHRMAN GJ, DUNSMORE R. Glioblastoma multiforme of the cerebellum. *Surg Neurol* 1975;3:219-23.
4. HEGEDUS K, MOLNAR P. Primary cerebellar glioblastoma multiforme with an unusually long survival: case report. *J Neurosurg* 1983;58:589-92.
5. OTA A, YAMADA S, SEMEJIMA N, TAKADA K, USUI M. A case of cerebellar glioblastoma with massive cerebellar hemorrhage. *No Shinkei Geka* 2001;29:1201-5.
6. YAMAMOTO M, FUKUSHIMA T, TSUGU H, NAGUSAKA S, HIRAKAWA K. Cerebellar gliomas with exophytic growth – 3 case reports. *Neuro Med Chir* 1997;37:411-5.
7. MATTOS JP, MARENCO HA, CAMPS JM, FARIOV AV, QUEIROZ LS, BORGES G, OLIVEIRA E. Cerebellar glioblastoma multiforme in an adult. *Arq Neuropsiquiatr* 2006;64:132-5.
8. WEBER DC, MILLER RC, VILLA S, HANSENS P, BAUMERT BG, CASTADOT P, VARLET P, ABACIOGLU U, UGDEM S, *et al.* Outcome and prognostic factors in cerebellar glioblastoma multiforme in adults: a retrospective study from the rare cancer network. *Int J Radiat Oncol Biol Phys* 2006;66:179-86.
9. CHIN HW, MARUYAMA Y, TIBBS P. Cerebellar glioblastoma in childhood. *J Neurooncol* 1994;2:79-84.
10. ROSENFELD J, ROSSI ML, BRIGS M. Glioblastoma multiforme of the cerebellum in an elderly man: a case report. *Tumor* 1989;75:62-9.

## Sažetak

### GLIOBLASTOM MALOGA MOZGA KOD STARIJE OSOBE – PRIKAZ SLUČAJA

*B. Božić, K. Rotim, A. Kogler, R. Broz, H. Krpina, H. Čupić i J. Radić*

Glioblastom maloga mozga je veoma rijedak. Dosad su u literaturi prikazana 33 bolesnika starije životne dobi s glioblastomom maloga mozga. Prikazan je slučaj muškarca u dobi od 65 godina. Kompjutorizirana tomografija maloga mozga pokazala je ekspanzivni proces maloga mozga veličine 34x33x52 mm. U kliničkoj slici je bila prisutna cerebelarna simptomatologija. Bolesnik je operiran u dva zahvata: najprije je zbog hipertenzijskog opstruktivnog hidrocefalusa učinjena vanjska ventrikularna drenaža, a u drugom zahvatu medijalna subokcipitalna kraniektomija i ablacija tumora. Histopatološki nalaz je ukazao na glioblastom maloga mozga. Poslijeoperacijski je provedeno onkološko liječenje koje je uključivalo radioterapiju i kemoterapiju temozolomidom.

**Ključne riječi:** *Moždane novotvorine – dijagnostika; Moždane novotvorine – kirurgija; Glioblastom – dijagnostika; Glioblastom – kirurgija; Starija dob; Prikaz slučaja*